Ultrasound Diagnosis and Evaluation of Plantar Heel Pain

Nicholas G. Argerakis, DPM*
Rock G. Positano, DPM, MSc, MPH†
Rock C. J. Positano, BS†
Ashley K. Boccio, BS*
Ronald S. Adler, MD, PhD‡
Gregory R. Saboeiro, MD†
Joshua S. Dines, MD†

Background: One of the most common causes of heel pain is plantar fasciitis; however, there are other pathologic disorders that can mimic the symptoms and clinical presentation of this disorder. The purpose of this study was to retrospectively review the prevalence of various pathologic disorders on ultrasound in patients with proximal plantar heel pain.

Methods: The medical records and diagnostic ultrasound reports of patients presenting with plantar heel pain between March 1, 2006, and March 31, 2007, were reviewed retrospectively, and the prevalence of various etiologies was collected. The inclusion criteria were based on their clinical presentation of plantar fasciitis or previous diagnosis of plantar fasciitis from an unknown source. Ultrasound evaluation was then performed to confirm the clinical diagnosis.

Results: We examined 175 feet of 143 patients (62 males and 81 females; age range, 16–79 years). Plantar fibromas were present in 90 feet (51%). Plantar fasciitis was diagnosed in 128 feet (73%). Coexistent plantar fibroma and plantar fascial thickening was found in 63 feet (36%). Of the 47 feet that were negative for plantar fasciitis on ultrasound, 27 (57%) revealed the presence of plantar fibroma.

Conclusions: Diagnostic ultrasound can effectively and safely identify the prevalence of various etiologies of heel pain. The high prevalence of plantar fibromas and plantar fascial tears cannot be determined by clinical examination alone, and, therefore, ultrasound evaluation should be performed for confirmation of diagnosis. (J Am Podiatr Med Assoc 105(2): 135-140, 2015)

It has been stated that approximately 10% of people will develop plantar fasciitis at some point in their life.[1] There are many different pathologic conditions that can cause heel pain, affecting approximately 2 million Americans annually.[2] The different etiologies can be accurately diagnosed through a clinical examination and appropriate diagnostic testing.

Ultrasound imaging of the plantar fascia can reveal the presence of pathologic conditions in patients with heel pain. Technical advances and higher-frequency transducers have made ultrasound technology more desirable than magnetic resonance imaging of musculoskeletal abnormalities owing to its higher spatial resolution.[3] Plantar fasciitis is documented as the most common condition causing heel pain.[4] Differentiating between plantar fasciitis and other entities has important clinical implications because the treatment protocols are different.

Plantar fasciitis is characterized by tension and inflammation of the plantar fascia.[5] Diagnosis of plantar fasciitis commonly involves clinical evaluation and a thorough history.[6,7] Initial treatment of plantar fasciitis consists of conservative measures, with pain resolution in 90% of patients.[8] Surgical intervention is reserved for patients who do not respond to conservative treatment regimens.

*Department of Surgery, New York College of Podiatric Medicine, New York, NY.
†Non-Surgical Foot and Ankle Service, Joe DiMaggio Sports Medicine Foot and Ankle Center, Hospital for Special Surgery, New York, NY.
‡New York University Langone Medical Center, New York, NY.
Corresponding author: Nicholas G. Argerakis, DPM, Department of Surgery, New York College of Podiatric Medicine, 53 E 124th St, New York, NY 10035. (E-mail: nargerakis@gmail.com)

Originally described by Ledderhose in 1897, plantar fibromatosis is a benign soft-tissue lesion characterized by proliferation of fibrous tissue in the plantar fascia.[9] The etiology of plantar fibromatosis is unknown.[10] The plantar nodules usually occur along the central and medial longitudinal portion of the plantar fascia in nonweightbearing areas of the foot. Plantar fibromatosis can be asymptomatic, but for palpable painful lesions, treatment options include conservative methods and surgical excision after conservative measures fail. Surgical excision is associated with a 40% to 86% recurrence rate.[11,12]

The purpose of this study was to retrospectively review the prevalence of etiologies in patients with heel pain. We hypothesize that the prevalence of sonographic abnormalities, such as plantar fibromatosis, is higher than previously reported in patients diagnosed as having plantar fasciitis. Owing to a low specificity of clinical diagnosis in patients with heel pain, presumptive diagnosis of plantar fasciitis may often be confused with other pathologic states. These can be identified through the use of ultrasound.

Materials and Methods

This was a retrospective review of all patients presenting to the Joe DiMaggio Non-surgical Foot and Ankle Center (New York, New York) with plantar and posterior heel pain between March 1, 2006, and March 31, 2007; it was approved by the institutional review board. During this 13-month period, 143 patients were examined and clinically diagnosed as having plantar fasciitis. Thirty-two of these patients had sonographic evaluation of both feet owing to bilateral foot pain, resulting in a total of 175 feet scanned for plantar fasciitis.

The inclusion criteria were based on patients' chief concern of plantar proximal heel pain, with clinical examinations consistent with plantar fasciitis (according to the 2010 clinical practice guidelines committee of the American College of Foot and Ankle Surgeons). Clinical diagnostic criteria consisted of pain on palpation of the plantar heel, localized swelling, pain on palpation of the proximal plantar fascia, and a history of pain on initiation of activity that resolves within a half hour of ambulation. Patients with history of trauma, those with previous plantar or posterior foot surgery, patients who previously had advanced imaging (computed tomography, ultrasound, or magnetic resonance imaging) of their feet, and patients with a palpable mass in the plantar fascia were excluded from this study.

All of the patients were examined and clinically diagnosed by one clinician (R.G.P.). Before undergoing an ultrasound examination, patients were assessed using standard anteroposterior, lateral, and medial oblique radiographs. The presence of heel spur was not contributory to arriving at the diagnosis of plantar fasciitis and, therefore, was not recorded in these data. The indication for performing ultrasound evaluation was patients who had proximal plantar heel pain and met the inclusion criteria.

All of the ultrasound examinations were performed using a high-frequency linear phased array transducer (L12-5) and an iU22 scanner (Philips Medical, Bothell, Washington) with proprietary software. Color Doppler was used. Scans were performed by a board-certified musculoskeletal radiologist (R.S.A.) trained in ultrasound imaging. A second board-certified radiologist (G.R.S.) skilled in ultrasonography reviewed various images and scored them independently for the presence of plantar fasciitis, plantar fascial tears, presence of fibroma, number of fibromas present, Morton's neuroma, adventitial bursitis, retrocalcaneal bursitis, and stress fractures of the calcaneus. Interobserver agreement was assessed in a blinded and independent manner by randomly selecting 30 images and comparing each radiologist's diagnosis. There was 100% interobserver agreement of diagnosis, not including descriptions of subclassifications of abnormalities.

Plantar fasciitis was diagnosed sonographically as greater than 4-mm thickening of the proximal medial band (level of the medial calcaneal tubercle) of the plantar fascia. The fascia was measured at its thickest site. Plantar fibroma was diagnosed as a discrete hypoechoic nodule in the medial band and separated from the origin.[13] There was no evidence of cystic change or calcification seen on ultrasound. The fibromas included in this study were homogeneous and without posterior acoustic enhancement. Plantar fascial tears were diagnosed as a discretely marginated hypoechoic or anechoic defect in the contour of the plantar fascia causing architectural distortion of the fascia.

In patients with plantar fibromas, we characterized the number, size, and location of the lesions. Also noted was the thickness of the plantar fascia in all of the patients with or without evidence of plantar fasciitis. Sonographic evaluation of all of the patients was performed before implementing a

treatment regimen, with sensitivity of 80.9% and specificity of 85.7%.[14]

Results

Of the 143 patients, 81 were female and 62 were male. Patient ages ranged from 16 to 79 years (mean, 53 years). One hundred eleven patients had unilateral ultrasound foot examinations, and 32 patients were referred for bilateral foot examination owing to bilateral foot pain, resulting in 175 feet scanned. Based on ultrasound results, plantar fasciitis was diagnosed in 128 of the 175 feet (73%). The average plantar fascial thickness in the 128 feet with plantar fasciitis was 6.2 mm (range, 4.5–9.8 mm). Forty-three of the 128 feet with plantar fasciitis (34%) also demonstrated concomitant plantar fascial tears on ultrasound. Forty-seven of the 175 feet scanned were negative for plantar fasciitis. The mean plantar fascial thickness of the 47 feet negative for plantar fasciitis was 3.5 mm (2.4–4.0 mm). Twenty-seven of the 47 feet negative for plantar fasciitis (57%) revealed the presence of at least one plantar fibroma.

Of the 175 feet scanned, 90 had fibromas (51%). Sixty-two of the 90 feet (69%) demonstrated one fibroma, 19 of the 90 feet (21%) had two fibromas, and nine of the 90 feet (10%) had three or more fibromas. The mean size of the fibromas was 8 mm longitudinally (range, 1–35 mm). The mean distance of the plantar fibroma from the plantar calcaneal insertion was 4.6 mm (range, 0–12 mm). The average plantar fascial thickness in the 27 patients with plantar fibroma without plantar fasciitis was 3.7 mm. No significant sex difference was observed in patients with plantar fibroma (35 men, 45 feet total and 38 women, 45 feet total).

Sixty-three feet had coexisting plantar fibroma and plantar fasciitis, and the mean plantar fascial thickening of these feet was 6.1 mm. Twenty of the 175 feet scanned (11%) showed no evidence of plantar fasciitis or plantar fibroma. In 11 of the 20 feet, the ultrasound examination findings were completely normal. The remaining nine of the 20 feet demonstrated the following abnormalities: Morton's neuroma (n = 2), adventitial bursitis (n = 1), retrocalcaneal bursitis (n = 1), partial (n = 2) or complete (n = 2) plantar facial tears, and stress fracture of the calcaneus (n = 1).

Discussion

We hypothesized that ineffective management of intractable plantar fasciitis may be caused by the undiagnosed presence of alternative pathologic disorders. This study demonstrates the usefulness of ultrasound in detecting differential diagnoses of plantar heel pain. Furthermore, these findings highlight the relatively poor success of clinical diagnosis.

The mainstay diagnosis of patients with clinically suspected plantar fasciitis is a thorough history and clinical examination. The findings consist of pain on palpation of the plantar heel, localized swelling, pain on palpation of the proximal fascia, and a history of pain on initiation of activity and resolving within a half hour of ambulation.[15] It is not uncommon for standard radiographs to be used as an initial imaging modality in these patients. Standard conventional radiographic images are often nondiagnostic for plantar fasciitis and other soft-tissue pathologic abnormalities that may cause similar clinical symptoms. Radiographs are useful for elucidating the presence of plantar fasciitis–related heel spurs, and although correlations have been found between calcaneal spurs and plantar heel pain,[16] the specific role has yet to be determined.

Ultrasound is gaining acceptance and has received increased attention owing to its widespread use in evaluation and diagnosis of musculoskeletal pathologic abnormalities.[17] Owing to advances in ultrasound technology, high-resolution imaging of soft-tissue abnormalities with high spatial resolution can be achieved. In addition, it is conducted in a cost-effective manner. When using ultrasound to examine musculoskeletal abnormalities, manipulation of the patient during the examination in a real-time and dynamic form allows for a more specific diagnostic capability.[14] This holds true especially in patients with plantar heel pain because the musculoskeletal radiologist can palpate the maximum point of tenderness and guide the probe toward the pathologic area. Tsai et al[18] determined that the use of ultrasound could confirm an initial diagnosis of plantar fasciitis. In 123 feet with plantar fasciitis, they found that hypoechoic plantar fascia and increased fascial thickness were consistent findings against the control group.

In the present study, an ultrasound examination was performed on every patient clinically suspected of having plantar fasciitis based on history and physical examination findings. Radiographic images were taken of all of the patients, but the presence or absence of a heel spur did not affect the decision to conduct an ultrasound study. Normally, on ultrasound, the plantar fascia is visualized as a less than 4-mm band of generally hyperechoic tissue with a

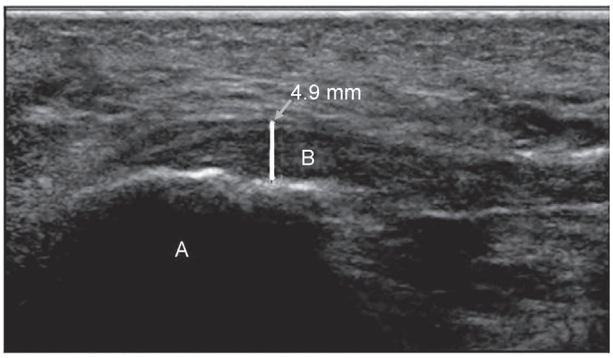

Figure 1. Longitudinal ultrasound image of the calcaneus (A) and the thickened plantar fascia (B).

striated appearance. When the plantar fascia is pathologically thickened (>4 mm), the band of tissue has decreased echogenicity (Fig. 1).

Of the 175 feet scanned using ultrasound, plantar fasciitis was found in 128 (73%). A 73% prevalence of fasciitis is low considering that plantar fasciitis is the most common cause of heel pain. The recommended initial diagnosis of fasciitis is based on clinical examination without the use of advanced imaging.[15] This could account for the low percentage of fasciitis in this study. In a previous study, the specificity and sensitivity of ultrasound diagnosis of plantar fasciitis were 86% compared with bone scintigraphy.[19] Tsai et al[18] reported that sensitivity of ultrasound in detecting plantar fasciitis was 91.9%, and specificity was 90.5%.

Factors that can be associated with the development of plantar fasciitis are ankle equinus, increased body mass index, and long periods of work-related weightbearing.[20] The only patient demographic factor analyzed in this study was sex. We found no difference in the prevalence of fasciitis or fibromas in males and females.

Initial treatment of plantar fasciitis is achieved through conservative measures, such as stretching, foot orthoses, and the use of anti-inflammatory agents. Prescription custom-made or prefabricated foot orthoses for the management of plantar fascia pain affect biomechanical factors, such as excessive pronation, and offload the plantar fascia at the origin.[21] Oral anti-inflammatory agents and corticosteroid injections have been effective to minimize inflammation of the plantar fascia.[22,23] In cases of intractable plantar fasciitis, more advanced modalities, including operative treatments, are available, such as partial fasciotomies at the origin of the plantar fascia.[24]

Plantar fibromatosis is a locally aggressive benign tumor that occurs in the palmar and plantar superficial tissues. Plantar fibromas located in the plantar fascia have a unique appearance. They are usually well-defined, heterogenic, hypoechoic masses along the plantar fascia band (Fig. 2). They are not hypervascular on color Doppler. Malignant tumors, although rare, tend to be hypervascular and do not clearly arise from the plantar fascia like benign fibromas. There were no malignant soft-tissue tumors diagnosed in the 175 feet scanned in this study.

Hafner et al[25] studied 100 pathology specimens of plantar fascia obtained from fasciectomies performed on patients diagnosed as having recalcitrant plantar fasciitis. Their results demonstrated that 25% of the specimens had plantar fibromas, suggesting fibromatosis as a possible cause of heel pain. Of the 175 feet included in this study, none had clinically palpable fibromas before ultrasound evaluation. Ultrasound examination revealed the prevalence of fibromas to be 51% (90 of 175 feet). In addition, 63 of the 128 feet demonstrating plantar fasciitis on ultrasound had coexisting fibromas. It is not known whether the plantar fibromas found in these patients were symptomatic; therefore, we cannot recommend altering treatment. However, the prevalence is much higher than previously reported, which brings into question the specificity of the current diagnostic techniques. Further research would be beneficial that follows patient outcomes after different treatments are used based on ultrasound diagnosis.

Once the diagnosis of plantar fibromatosis is established with the coexistence of pain, conservative therapy is initiated. Oral anti-inflammatory

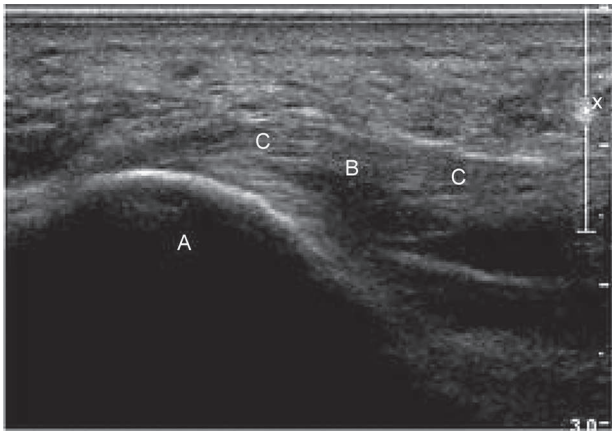

Figure 2. Longitudinal ultrasound image of the left hindfoot with a small deep surface partial-thickness tear. A indicates the calcaneus; B, partial-thickness tear in the plantar fascia; and C, normal plantar fascia without tear.

medication can be used for immediate relief of symptoms, and injection of corticosteroid directly into the tumor, as opposed to the insertion of the plantar fasciitis, has been suggested. Prescription foot orthoses with isolated depressions can alleviate the weightbearing demand directly under the palpable fibromas. Surgical intervention is indicated when painful symptoms are unresponsive to conservative treatment.[26] However, we do not routinely intervene surgically because of the significantly high recurrence rate.[27] This makes it difficult to obtain histologic specimens. A major limitation in this study is that the specificity of the diagnosis, although assumed to be high, is not exactly known because there was no histologic confirmation.

Tears in the plantar fascia are visualized under ultrasound as discretely marginated defects (Fig. 3). Acute tears of the fascia often displayed power Doppler hyperemia and regional edema with irregular fascial margins. Chronic tears in our patients had smoother margins secondary to remodeling, with normal surrounding tissues and no power Doppler flow. Owing to the difficulty in distinguishing acute from chronic, the fascial tears were not categorized as such and were recorded in the data as fascial tears. Perifascial fluid accumulation was not used to identify partial fascial tears. In addition, owing to the planar nature of sonography, possible surface defects associated with partial tears may not always be visualized.

Differentiating chronic fascial tears from fibromas can occasionally be difficult. A completely remodeled tear can have an oval, contour-deforming appearance, similar to a fibroma. However, the remodeled tear is usually more inhomogeneous than a fibroma. In addition, plantar fascial tears tend to occur in close proximity to the calcaneal attachment of the fascia, whereas fibromas occur more distally. Identification of acute or chronic fascial tears is essential before treatment of fasciitis, especially if the treating physician is considering a corticosteroid injection.

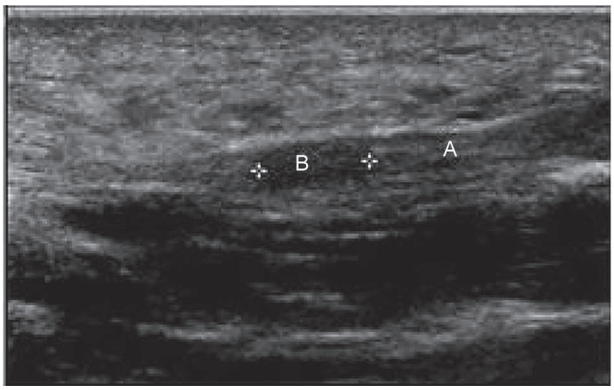

Figure 3. Longitudinal view of a plantar fibroma appearing as an irregular hypoechoic mass in the plantar fascia. A indicates normal plantar fascia; B, fibroma in the plantar fascia.

Acevedo and Beskin[28] found that 12 of 44 plantar fascial ruptures (27%) were due to corticosteroid injections. They concluded that corticosteroid injection should be used with caution in patients with fasciitis owing to the risk of rupture. In the present study, 43 of the 128 feet with plantar fasciitis (34%) also demonstrated the presence of plantar fascial tears. This finding is significant because unguided corticosteroid injection into the plantar fascia subjects patients not only to the inherent risks of infection, bleeding, and local tissue injury but also to an increased risk of rupture of the plantar fascia.[28] Although it was not demonstrated with the present data, there may be a possible correlation with unsuccessful treatment, or increased ruptures in patients treated with corticosteroid injection for plantar fasciitis, due to undiagnosed plantar fascial tears.

Additional etiologies of heel pain consist of calcaneal stress fractures, plantar xanthomas, tumors, fat pad atrophy, inflammatory arthritides, and neurologic manifestations. The present ultrasound examination did not aim to diagnose all possible causes of heel pain. Nine of 20 feet negative for plantar fasciitis or plantar fibroma showed various etiologies, including Morton's neuroma, adventitial bursitis, retrocalcaneal bursitis, plantar facial tears, and stress fracture of the calcaneus. The remaining 11 of 20 feet were completely normal on ultrasound examination. These feet can have underlying etiologies, such as entrapment neuropathy, inflammatory arthritis, or fat pad atrophy, which were not evaluated on ultrasound. These patents would require additional diagnostic modalities and workup.

Conclusions

This article demonstrates that through the use of diagnostic ultrasound, patients who present with plantar heel pain can be more effectively diagnosed and managed. Although the ultrasound examination does not determine the cause of plantar heel pain, it highlights the relatively poor specificity of clinical diagnosis due to a higher-than-expected prevalence of unsuspected etiologies. These patients may actually have a different diagnosis or a combination of these pathologic abnormalities causing their

plantar heel pain. This study illustrates the importance of the use of ultrasound in making the correct initial diagnosis in patients with plantar heel pain owing to the inaccuracy of clinical diagnosis.

Financial Disclosure: None reported.
Conflict of Interest: None reported.

References

1. Riddle DL, Schappert SM: Volume of ambulatory care visits and patterns of care for patients diagnosed with plantar fasciitis: a national study of medical doctors. Foot Ankle Int **25:** 303, 2004.
2. McPoil TG, Martin RL, Cornwall MW, et al: Heel pain: plantar fasciitis: clinical practice guidelines linked to the international classification of function, disability, and health from the orthopaedic section of the American Physical Therapy Association. Orthop Sports Phys Ther **38:** A1, 2008.
3. Adler R, Sofka C, Positano R: "General Principles," in *Atlas of Foot and Ankle Sonography*, edited by L McAllister, J Bersin, M McLaughlin, et al, p 1, Lippincott Williams & Wilkins, Philadelphia, 2004.
4. League AC: Current concepts review: plantar fasciitis. Foot Ankle Int **29:** 358, 2008.
5. Barrett SJ, O'Malley R: Plantar fasciitis and other causes of heel pain. Am Fam Physician **59:** 2200, 1999.
6. Jahss MH: "Surgery of the Adult Heel," in *Disorders of Foot and Ankle: Medical and Surgical Management*, 2nd Ed, WB Saunders, Philadelphia, 1982.
7. La Porta GA, La Fata PC: Pathologic conditions of the plantar fascia. Clin Podiatr Med Surg **22:** 1, 2005.
8. Davis PF, Severud E: Painful heel syndrome: results of nonoperative treatment. Foot Ankle Int **15:** 531, 1994.
9. Ledderhose G: Zur pathologic der aponeurose des Fusses und der Hand. Arch Klin Chir **55:** 694, 1897.
10. Zgonis T, Jolly GP, Polyzois V, et al: Plantar fibromatosis. Clin Podiatr Med Surg **22:** 11, 2005.
11. Aluisio FV, Mair SD, Hall RL: Plantar fibromatosis: treatment of primary and recurrent lesions and factors associated with recurrence. Foot Ankle Int **17:** 672, 1996.
12. Durr HR, Krodel A, Trouillier H, et al: Fibromatosis of the plantar fascia: diagnosis and indications for surgical treatment. Foot Ankle Int **20:** 13, 1999.
13. Adler R, Sofka C, Positano R: "Hindfoot," in Atlas of Foot and Ankle Sonography, edited by L McAllister, J Bersin, M McLaughlin, et al, p 73, Lippincott Williams & Wilkins, Philadelphia, 2004.
14. Sabir N, Demirkienk S, Yagci B, et al: Clinical utility of sonography in diagnosis plantar fasciitis. J Ultrasound Med **24:** 1041, 2005.
15. Thomas JL, Christensen JC, Kravitz SR, et al; American College of Foot and Ankle Surgeons Heel Pain Committee: The diagnosis and treatment of heel pain: a clinical practice guideline-revision 2010. J Foot Ankle Surg **49** (suppl)**:** S1, 2010.
16. Erickson SJ: High-resolution imaging of the musculoskeletal system. Radiology **205:** 593, 1997.
17. Williams PL, Smibert JG, Cox R, et al: Imaging study of the painful heel syndrome. Foot Ankle **7:** 345, 1987.
18. Tsai WC, Chiu MF, Wang CL, et al: Ultrasound evaluation of plantar fasciitis. Scand J Rheumatol **29:** 255, 2000.
19. Kane D, Greaney T, Shanahan M, et al: The role of ultrasonography in the diagnosis and management of idiopathic plantar fasciitis. Rheumatology (Oxford) **40:** 1002, 2001.
20. Riddle DL, Pulisic M, Pidcoe P, et al: Risk factors for plantar fasciitis: a matched case-control study. J Bone Joint Surg Am **85:** 872, 2003.
21. Kogler GF, Solomonidis SE, Paul JP: In vitro method for quantifying the effectiveness of the longitudinal arch support mechanism of a foot orthosis. Clin Biomech (Bristol, Avon) **10:** 245, 1995.
22. Crawford F, Atkins D, Young P, et al: Steroid injection for heel pain: evidence of short-term effectiveness: a randomized controlled trial. Rheumatology (Oxford) **38:** 974, 1999.
23. Donley BG, Moore T, Sferra J, et al: The efficacy of oral nonsteroidal anti-inflammatory medication (NSAID) in the treatment of plantar fasciitis: a randomized, prospective, placebo-controlled study. Foot Ankle Int **28:** 20, 2007.
24. Daly PJ, Kitaoka HB, Chao EY: Plantar fasciotomy for intractable plantar fasciitis: clinical results and biomechanical evaluation. Foot Ankle **13:** 188, 1992.
25. Hafner S, Han N, Pressman MM, et al: Proximal plantar fibroma as an etiology of recalcitrant plantar heel pain. J Foot Ankle Surg **50:** 153, 2011.
26. Veith NT, Tschernig T, Histing T, et al: Plantar fibromatosis: topical review. Foot Ankle Int **34:** 1742, 2013.
27. Aluisio FV, Mair SD, Hall RL: Plantar fibromatosis: treatment of primary and recurrent lesions and factors associated with recurrence. Foot Ankle Int **17:** 672, 1996.
28. Acevedo JI, Beskin JL: Complications of plantar fascia rupture associated with corticosteroid injection. Foot Ankle Int **19:** 91, 1998.